










Supplementary information to:

Letter to the editor:

**FIRST CASE OF LUCIO'S PHENOMENON IN A LEPROMATOUS
LEPROSY PATIENT FOLLOWING COVID-19 VIRAL VECTOR
VACCINE**

Roberto Fernandes Soares-Neto¹, Geysse Maria Lima da Piedade¹, Priscila Soares Pereira¹, Rebeca Yasmin Ribeiro Vieira², Jerocilio Maciel de Oliveira-Júnior^{3,4}, Thalyta Porto Fraga⁵, Martha Débora Lira Tenório^{1,3,4}, Pedro Dantas Oliveira⁶, Paulo Ricardo Martins-Filho^{3,4*}

¹ Residency Program in Dermatology, University Hospital, Federal University of Sergipe, Brazil

² Residency Program in Infectious Diseases, University Hospital, Federal University of Sergipe, Brazil

³ Graduate Program in Health Sciences, Federal University of Sergipe, Brazil

⁴ Investigative Pathology Laboratory, Federal University of Sergipe, Brazil

⁵ Laboratory of Pathological Anatomy, University Hospital, Federal University of Sergipe, Brazil

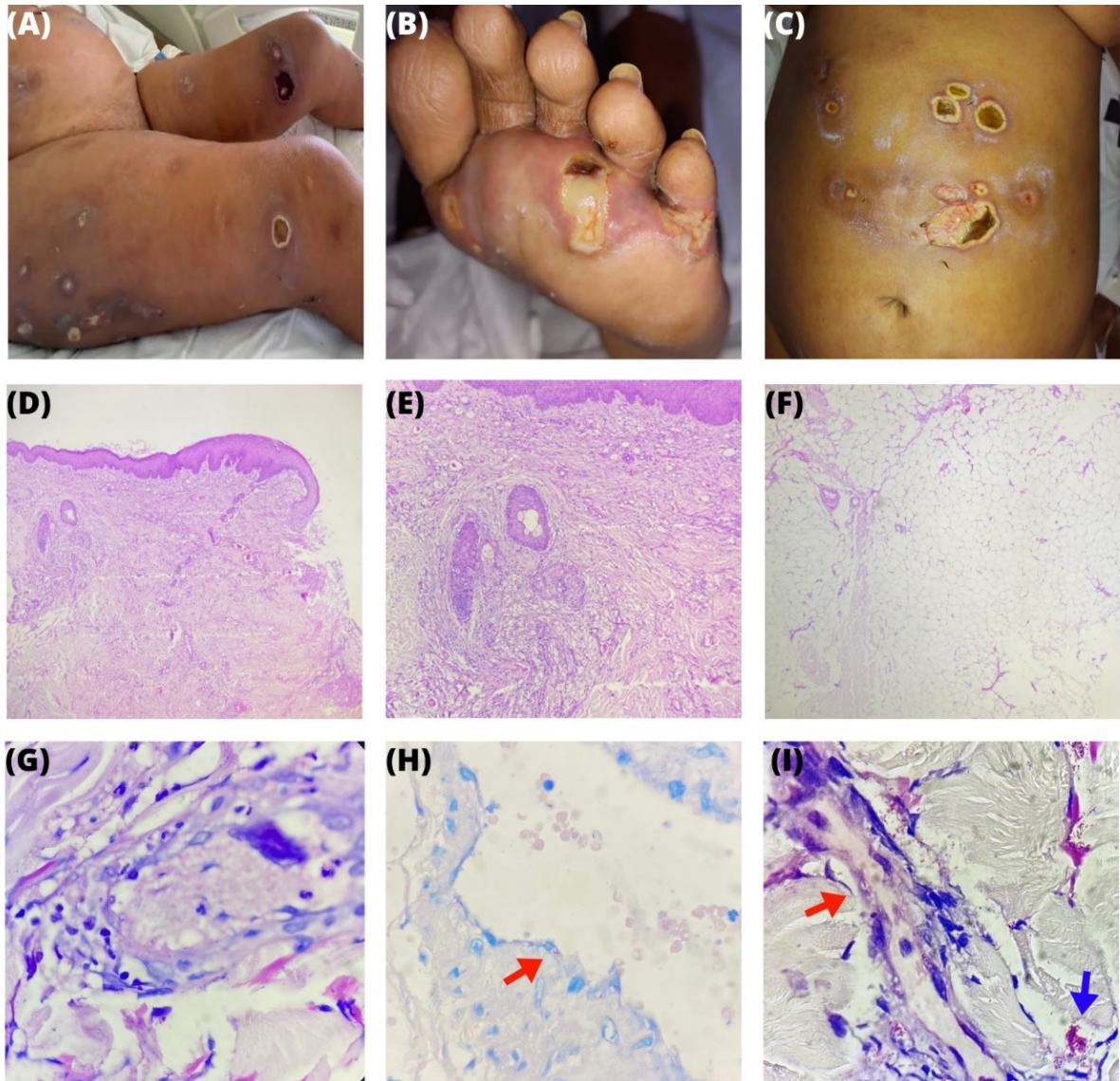
⁶ Department of Medicine, Federal University of Sergipe, Brazil

* **Corresponding author:** Prof. Paulo Ricardo Martins-Filho, Universidade Federal de Sergipe, Hospital Universitário, Laboratório de Patologia Investigativa. Rua Cláudio Batista, s/n. Sanatório. Aracaju, Sergipe, Brasil. CEP: 49060-100.

E-mail: prmartinsfh@gmail.com

<https://dx.doi.org/10.17179/excli2023-6661>

This is an Open Access article distributed under the terms of the Creative Commons Attribution License (<http://creativecommons.org/licenses/by/4.0/>).



Supplementary Figure 1: (A-C) Necrotic ulcers with violaceous erythematous borders on the abdomen and lower limbs; (D) Peripheral ulceration site showcasing a moderate dermal lymphohistiocytic inflammatory infiltrate (H-E stain, ×100); (E) Lymphohistiocytic inflammatory presence around pilosebaceous follicles (H-E stain, ×100); (F) Intact hypodermis with sporadic lymphohistiocytic inflammatory foci surrounding blood vessels (H-E stain, ×100); (G) Vessel depicted with mixed inflammatory infiltration within its wall and noticeable moderate edema; an adherent thrombus is visible within the lumen (H-E stain, ×400); (H-I) Ziehl-Neelsen staining reveals abundant AFBs, a mix of fragmented and intact. Red arrows pinpoint an AFB within the vessel endothelium, while a blue arrow indicates globias (Ziehl-Neelsen stain, ×400).