

Original article:

EXTRACT OF *FERULA FOETIDA* REGEL REVERSES GENTAMICIN-INDUCED NEPHROTOXICITY IN RATS

Rasikh Javaid^{1*}, Mohd Aslam¹, Raheela Javaid², Qudsia Nizami¹, Kalim Javed³,
M.U. Azhar⁴

¹ Department of Ilmul Advia (Pharmacology), Faculty of Medicine (U), Jamia Hamdard, New Delhi, India

² Department of Moalijat, Faculty of Medicine (U), Jamia Hamdard, New Delhi, India

³ Department of Chemistry, Faculty of Science, Hamdard University, New Delhi, India

⁴ Research Officer (Scientist II), Central Council of Research in Unani Medicine, Janakpuri, New Delhi, India

* corresponding author: Rasikh Javaid, Department of Ilmul Advia (Pharmacology), Faculty of Medicine (U), Jamia Hamdard, New Delhi 110062, India;
E-mail address: drrasikh@gmail.com; Mobile No. +91 9716602197

ABSTRACT

Natural products and dietary components have earlier been proven as potential chemoprotective agents, and continuous efforts are in progress to search for such new products. Gentamicin, an aminoglycoside antibiotic, is widely used for treating the infections caused by many gram negative bacteria. However, besides other unwanted effects, the drug causes tubular cell necrosis in the proximal convoluted tubules of nephrons. Unavailability of any remedial measures in the modern medicine for such ailments therefore makes it imperative to screen for natural products that are nephroprotective against such renal impairment. Here in the undertaken study, we have tested nephroprotective effects of Hing (*Ferula foetida*) extracts on gentamicin-treated rats. As expected, subcutaneous administration of rats with Gentamicin (100 mg/kg) showed significant increase in blood urea nitrogen (BUN), serum creatinine and thiobarbituric acid reacting substances (TBARS), as an indication of renal disorder. However, co-administration of methanol soluble and insoluble fractions of *Ferula foetida* (Hing), to the Gentamicin-treated rats almost showed a complete reversal of the above effects, indicating nephroprotective properties of the herbal drug. This may be an important addition to the list of studies where natural products have been discovered to be chemoprotective.

Keywords: *Ferula foetida*, gentamicin, nephrotoxicity, serum creatinine, blood urea nitrogen

INTRODUCTION

Ferula foetida (Hing), a small herb of the family Umbelliferae is known for its medicinal values. The plant is well recognized for nervine stimulation (Kokate et al., 2003), emmenagogue and diuretic (Nadkarni, 1989), properties in Indian medicine system and as anti-inflammatory (Khan, 1912), diuretic (Lubhaya, 1984; Ibn-e-Sina et al.,

1927; Ibn-e-Baitar, 1999; Ghani, 1920) and anti-spasmodic (Kabiruddin, 1951) in Unani system of medicine. The ineffectiveness of the modern medical techniques against the current prevalent diseases like obesity, hypertension, diabetes, heart and kidney disorders, schizophrenia, Parkinsonism, increased cancer and other latest health issues, once again the natural holistic thera-

pies are being preferred. Besides the disease itself, management of chemical side effects of the drugs administered, has become a major issue, nephrotoxicity forms one of the inherent adverse off-effect of certain antibiotics, anticancer drugs and other synthetic molecules. A number of extracts of natural products and dietary antioxidants have earlier been reported to be protective against nephrotoxicity (Javaid et al, 2012a). The present work was undertaken to evaluate the efficacy of Hing for its nephroprotective effects against Gentamicin-induced nephrotoxicity.

MATERIALS AND METHODS

Plant material

The exudate of the Hing (oleo-gum resin of *Ferula foetida* Linn) was purchased from Hari Gokhal Khari Baoli and the botanical identity was established as *Ferula assafoetida* (Hing) at National Institute of Science Communication and Information Resources (Dr. K.S. Krishnan Marg, Pusa Gate, New Delhi, 110012) under Ref. NISCAIR/RHMD/Consult/-2008-09/970/01 (dated 1st April, 2008). A voucher specimen has been preserved in the Department of IImul Advia, Faculty of Medicine Jamia Hamdard, New Delhi 110062, India.

Preparation of extracts

Dried exudate (100 gm) of Hing was refluxed with 100 % methanol for 3 hrs, in a distillation flask over a boiling water bath, cooled at room temperature and filtered. The plant material obtained after filtration was re-extracted twice by the same procedure and the extracts were mixed together.

Methanol was removed by distillation under reduced pressure. The yield of methanol soluble (MS-FF) and methanol insoluble (MI-FF) fractions was 25 % and 75 % respectively in the terms of exudate.

Animal experiments

All animal experiments were carried out both on male as well as female albino rats of Wistar strain (body weight ~180-250 g), supplied by the Central Animal House Facility of Jamia Hamdard, New Delhi (Registration no. 173/CPSEA). All animal groups were kept in polypropylene cages and maintained on a standard pellet diet (Amrut Laboratory rat and mice feed, New Maharashtra Chakan Oil Mills Ltd., Mumbai) and water *ad libitum* at 25 ± 1 °C temperature. The experiments were performed in accordance with guidelines of the Committee for the Purpose of Control and Supervision of Experiments in Animals (CPCSEA), Ministry of Social Justice and Empowerment, Govt. of India, Jan. 2000. In all experiments 1 % carboxy methyl cellulose (CMC) (Central Drug House Ltd. Bombay) was used as vehicle in water and doses given at 10 ml/kg of body weight. All drug treatments were given as vehicular suspension (10 ml/kg of body weight). Gentamicin (Cadila Healthcare Ltd. Ahmedabad) was used as nephrotoxicant at 100 mg/kg body weight (Walker and Shah, 1988) and administered subcutaneously in neck region as 1 ml/kg doses.

Table 1 shows details of the drug treatment on different experimental animal groups.

Table 1: Treatment schedule

Groups	Treatment
I (Control)	1 % CMC as vehicle in water (10 ml/kg)
II (Toxicant) (Gentamicin)	Vehicle (1 % CMC in water, 10 ml/kg) + Gentamicin, (100 mg/kg) administered subcutaneously (1 ml/kg) in neck region for 8 days
III (MS-FF)	MS-FF suspension in vehicle, (10 ml/kg), and 68 mg per orally (p.o) + Gentamicin (100 mg/kg) given subcutaneously (1 ml/ kg) in neck region for last 4 days
IV (MI-FF)	MI-FF suspension in vehicle (10 ml/kg), p.o 352 mg + Gentamicin (100 mg/kg subcutaneously in neck region for last 4 days)

The animals in groups III and IV were co-administered with 100 mg/kg gentamicin (Walker and Shah, 1988) subcutaneously in neck region from day four to eight. Group I received normal saline (10 ml/kg) instead of gentamicin and group 2 was given gentamicin 1 ml/kg (of 100 mg/kg) for eight days.

Histopathological analysis

Animals were ether anaesthetized on 9th day and blood collected from retro-orbital plexus. For separation of serum from coagulated blood, the sample was left at room temperature for two hours, followed by 30 min centrifugation at 5000 rpm. The sera were estimated for blood urea nitrogen (BUN) and serum creatinine (Godkar, 1994). The animals were finally sacrificed under deep ether anaesthetization and kidneys removed, weighed and washed with normal saline. Kidney tissues were fixed in 10 % formalin saline, followed by the routine Hematoxylin and Eosin (H & E) staining. The tissues were estimated for thiobarbituric acid reacting substances (TBARS) (Ohkawa et al., 1979) and also examined for morphological changes, if any.

Statistical analysis

The estimated values for BUN, serum creatinine and TBARS are presented as mean \pm S.E (standard error) and percent inhibition by the test drug versus nephrotoxin. Percent inhibition was calculated by normalizing all estimated values (for BUN/serum creatinine/and TBARS) against that of the control. A 100 and 0 % inhibition indicates complete and no reduction of toxin-induced increase in the biochemical parameters, respectively. Statistical significance was evaluated by one way analysis of variance (ANOVA) followed by Dunnett's post hoc test.

RESULTS

Effect of Hing on biochemical parameters

Evaluation of BUN and serum creatine levels in blood is often used as indicative of renal function. The effect of Hing exudates on BUN and serum creatine in gentamicin-treated rats is summarized in Tables 2 and 3, respectively. As evident from the tables, the administration of Hing significantly reduced both BUN and serum creatine levels in groups III and IV when compared to that of group II. The mean values for BUN in groups I, II, III and IV were 12.06 ± 0.91 , 36.89 ± 2.26 , 11.72 ± 1.63 and 11.34 ± 0.48 , respectively and the toxicity inhibition percents for groups III and IV were 100 (Table 2).

Similarly, the mean values for serum creatinine in groups I, II, III and IV were, 1.60 ± 0.03 , 2.56 ± 0.02 , 1.70 ± 0.08 and 1.75 ± 0.03 , respectively and that the toxicity percent inhibitions in III and IV were 89.59 and 84.38, respectively (Table 3). The inhibition in rise of serum creatinine level was 10.41 % and 15.62 % for doses 70 and 350 mg/kg, respectively. Gentamicin is known to induce renal cortex lipid peroxidation in rats (Ramsammy et al., 1985) and is often reflected by change in thiobarbituric reagent substances (TBARS) in kidneys. Effect of Hing exudates on TBARS levels in gentamicin-treated rat kidneys are shown in Table 4. The mean TBARS value for groups I, II, III and IV were 8.81 ± 0.20 , 11.96 ± 0.08 , 9.21 ± 0.12 and 9.25 ± 0.05 , respectively. The percent toxicity inhibitions in the groups III and IV were 87.31 and 86.04, respectively, with the inhibition in rise of TBARS level as 12.69 and 13.96 %, respectively.

Table 2: Effect of methanol soluble and insoluble fractions of *Ferula foetida* on BUN levels in gentamicin-induced nephrotoxicity in rats

Groups	Treatment	Dose	BUN (mg/dl) Mean ± S.E	% Inhibition	% Rise
I (Control)	Vehicle	10 ml/kg	12.06 ± 0.91	-	
II (Toxicant)	Gentamicin	100 mg/kg	36.89 ± 2.26*	-	
III	MS-FF(LD)	70 mg/kg	11.72 ± 1.63 [#]	100 %	Nil
IV	MI-FF(HD)	350 mg/kg	11.34 ± 0.48 [#]	100 %	Nil

The mean value ± S.E was estimated from six replicate animals; statistically significant: *p<0.01 and [#]p<0.01, with that of toxicant group represent statistical significance in comparison with the control and toxicant groups. Group II was compared with all other groups by one way ANOVA followed by Dunnet's post hoc test.

Table 3: Effect of methanol soluble and insoluble fractions of *Ferula foetida* on serum creatinine levels in gentamicin-induced nephrotoxicity in rats

Groups	Treatment	Dose	Creatinine (mg/dl) Mean ± SE	% Inhibition	% Rise
I (Control)	Vehicle	10 ml/kg	1.60 ± 0.03	-	
II (Toxicant)	Gentamicin	100 mg/kg	2.56 ± 0.02**	-	
III	MS-FF(LD)	70 mg/kg	1.70 ± 0.08 ^{###}	89.59 %	10.41 %
IV	MI-FF(HD)	350 mg/kg	1.75 ± 0.03 ^{###}	84.38 %	15.62 %

The mean value ± S.E was estimated from six replicate animals; statistically significant: **p<0.01 and ^{###}p<0.01, represent statistical significance in comparison with the control and toxicant groups. Group II was compared with all other groups by one way ANOVA followed by Dunnet's post hoc test.

Table 4: Effect of Methanol soluble and insoluble fractions of *Ferula foetida* on TBARS in gentamicin - induced nephrotoxicity in rats

Groups	Treatment	Dose	TBARS (n moles MDA/mg protein) Mean ± SE	% Inhibition	% Rise
I (Control)	Vehicle	10 ml/kg	8.81 ± 0.20	-	
II (Toxicant)	Gentamicin	100 mg/kg	11.96 ± 0.08***	-	
III	MS-FF	140 mg/kg	9.21 ± 0.12 ^{###}	87.31 %	12.69 %
IV	MI-FF	350 mg/kg	9.25 ± 0.05 ^{###}	86.04 %	13.96 %

The mean value ± S.E was estimated from six replicate animals; statistically significant: ***p<0.001 and ^{###}p<0.01 represent statistical significance in comparison with the control and toxicant groups, Group II was compared with all other groups by one way ANOVA followed by Dunnet's post hoc test.

Overall, the above results suggest that administration of Hing exudates to gentamicin-treated rats, in two different doses of methanol soluble and insoluble fractions reduce the BUN, serum creatinine and TBARS levels significantly. This indicates that Hing is indeed capable of reversing the gentamicin-induced nephrotoxic effects in the treated rats.

Histopathological analysis

Examination of the gentamicin-treated rat kidney sections on 9th day, in comparison to the control group (Figure 1A), showed marked congestion of the glomeruli with numerous tubular casts associated with epithelial desquamation, marked peritubular congestion and edema. The interstitium showed infiltration with inflammatory cells and congestion. All these features are sug-

gestive of gentamicin-induced acute tubular necrosis. Administration of the rats with MS-FF and MI-FF of *Ferula foetida* showed reversal of the gentamicin-induced deformity of the kidney tissues, although few minor changes still persisted (Figure 1B and C and Table 5).

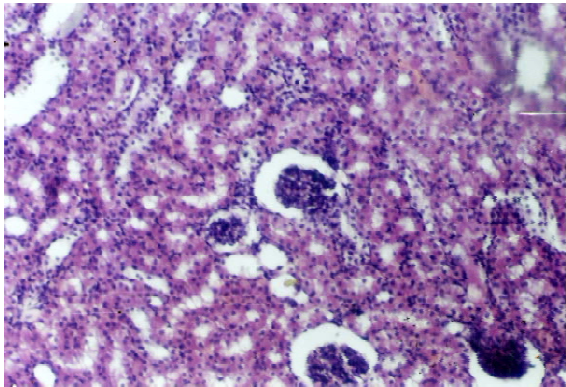


Figure 1A: Normal kidney tissues of rat (Control group)

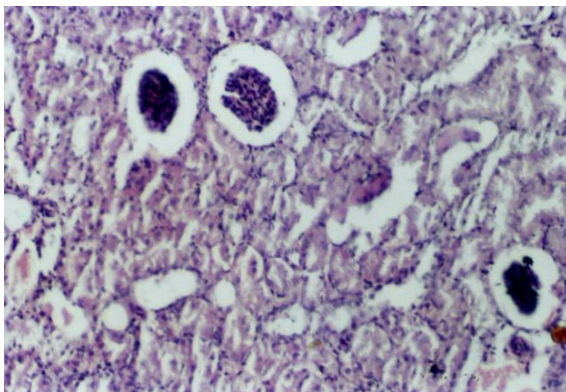


Figure 1B: MS-FF of *Ferula foetida* (Hing) treated rat showing tubular cell necrosis of kidney tissues in gentamicin-induced nephrotoxicity

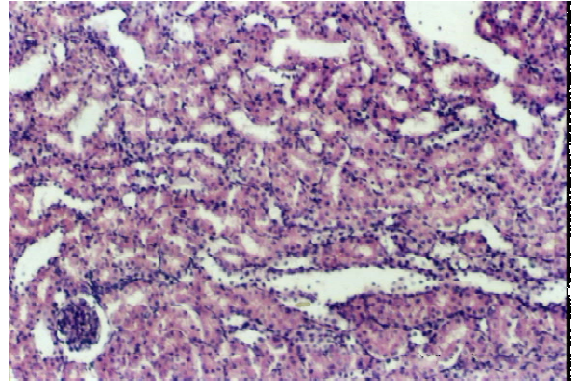


Figure 1C: MI-FF of *Ferula foetida* (Hing) treated rat showing normal kidney tissues in gentamicin-induced nephrotoxicity model

Table 5: Comparative histopathological analysis of the differently treated animal groups

Histological features	Control	Gentamicin	MS of <i>F. foetida</i>	MI of <i>F. foetida</i>
Glomerular congestion	-	++	+	-
Tubular casts	-	++	-	-
Peritubular congestion	-	++	-	-
Epithelial desquamation	-	++	-	-
Blood vessel congestion	-	++	-	-
Interstitial edema	-	++	-	-
Inflammatory cells	-	++	+	-

DISCUSSION

With relative ineffectiveness of the current medical methods against many present day diseases, referral to the natural holistic therapies (Javaid et al., 2012b) is on rise again. Plants have not only been the source of drug molecules but also produce drug-transformable feedstock molecules. Scientific research is yet to reach the climax in exploiting plants fully as a source of new drugs. Out of the estimated 250,000 species of flowering plants, < 10 % of them has been investigated for medicinal properties.

A number of antibiotics including the penicillins, cephalosporins, tetracyclines as well as the aminoglycosides and sulphonamides are potential nephrotoxins. Aminoglycoside nephrotoxicity is manifested functionally as decreased urine concentrating capacity and ammonium excretion, tubular proteinuria, lysosomal enzymuria, mild glucosuria, and depression of glomerular filtration rate (Kaloyanides and Pastoriza-Munoz, 1980).

Gentamicin, a widely used antibiotic against gram negative bacteria, is known to cause tubular cell necrosis in proximal convoluted tubules of nephron (Houghton et al., 1976) with increase in blood urea and serum creatinine. Taking into consideration the well defined measures of nephrotoxicity, the incidence rate for gentamicin has been reported to be 7-36 %. Kahlmeter and Dahlager (1984) have reported that average incidence of gentamicin nephrotoxicity is ~15 %.

Ferula foetida was treated with 100 % methanol for obtaining the methanol soluble and insoluble fractions. Being an oleo-gum resin in nature, oleo-resin and gum were fractionated as methanol soluble and insoluble, respectively. Eight day treatment of rats with methanol soluble (70 mg/kg) and insoluble (350 mg/kg) fractions of *Ferula foetida*, including gentamicin administration on 4th day, inhibited the rise in blood urea nitrogen (BUN), serum creatinine and TBARS. However, the effect of both doses was comparatively similar. Also, the histopathological examination of the

gentamicin-treated rat kidney tissues showed marked reduction in glomerular congestion, tubular casts, peritubular congestion, epithelial desquamation, blood vessel congestion, interstitial edema and inflammatory cells, post the administration of Hing derived methanol fraction. This finding indicates that *Ferula foetida* contains at least two active constituents and hence, further work needs to be done to characterize the fractions in detail and to understand their pharmacological potentials fully. Though the past several years have seen very few natural compounds in finding place as conventional medicine, yet the pharmacological research is teeming with interesting results and hopefully in near future, some new molecules can be added to the existing list.

REFERENCES

- Ghani MN. Khazain-ul-advia (pp 1070-2). Lahore, Pakistan: Sheikh Basheer Ahmad & Sons, 1920.
- Godkar PB. Clinical biochemistry: principles and practice (pp 118-32, 233-51). Bombay: Bhalani Publ. House, 1994.
- Houghton DC, Harnett M, Campbell-Boswell M, Porter G, Bennett W. A light and electron microscope analysis of gentamicin nephrotoxicity in rats. Am J Pathol 1976; 82:589.
- Ibn-e-Baitar. Aljamiul mufradat al advia wal aghzia (Urdu). Vol. III (pp 58-60, 170-3). New Delhi: CCRUM, 1999.
- Ibn-e-Sina. Alqanoon fit tibb (Urdu translation by Ghulam Hasnain Kantoori). Vol. II (pp 102-3, 159-63). Lahore: Sheikh Mohammad Bashiir & Sons, 1927.
- Javaid R, Aslam M, Nizami Q, Javaid R. Role of antioxidant herbal drugs in renal disorders: an overview. Free Rad Antioxid 2012a; 2:2-5.

Javaid R, Aslam M, Javaid R, Nizami Q. Nephroprotective effect of *Ferula foetida* (hing) in cisplatin induced nephrotoxicity. Int J Univ Pharm Life Sci 2012b;2:318-27.

Kabiruddin M. Makhzanul mufradat (pp 261, 289-91). Lahore: Sheikh Mohammad Bashir & Sons, 1951.

Kahlmeter G, Dahlager JI. Aminoglycoside toxicity: a review of clinical studies published between 1975 and 1982. J Antimicrob Chemother 1984;13(Suppl A):9-22.

Kaloyanides GJ, Pastoriza-Munoz E. Aminoglycoside nephrotoxicity. Kidney Int 1980;18:571-82.

Khan A. Muheetul Azam Dar matba nizami waqah Kanpur 1912; 211-2.

Kokate CK, Purohit AP, Gokhale SB. Pharmacognosy (pp 342-4, 402-4). Bombay: Nirali Prakashan, 2003.

Lubhaya RH. Goswami bayanul advia. Goswami pharmacy gali qasim jan (pp 73-5). New Delhi, 1984.

Nadkarni KM. Indian materia medica. Pt. I (328-30, 537-40). Bombay: Bombay Popular Prakashan, 1989.

Ohkawa H, Ohishi N, Yagi K. Assay for lipid peroxides in animal tissues by thiobarbituric acid reaction. Anal Biochem 1979;95:351-8.

Ramsammy L, Ling KY, Josepovitz C, Levine R, Kaloyanides GJ. Effect of gentamicin on lipid peroxidation in rat renal cortex. Biochem Pharmacol 1985;34:3895-900.

Walker PD, Shah SV. Evidence suggesting a role for hydroxyl radical in gentamicin-induced acute renal failure in rats. J Clin Invest 1988;81:334-41.