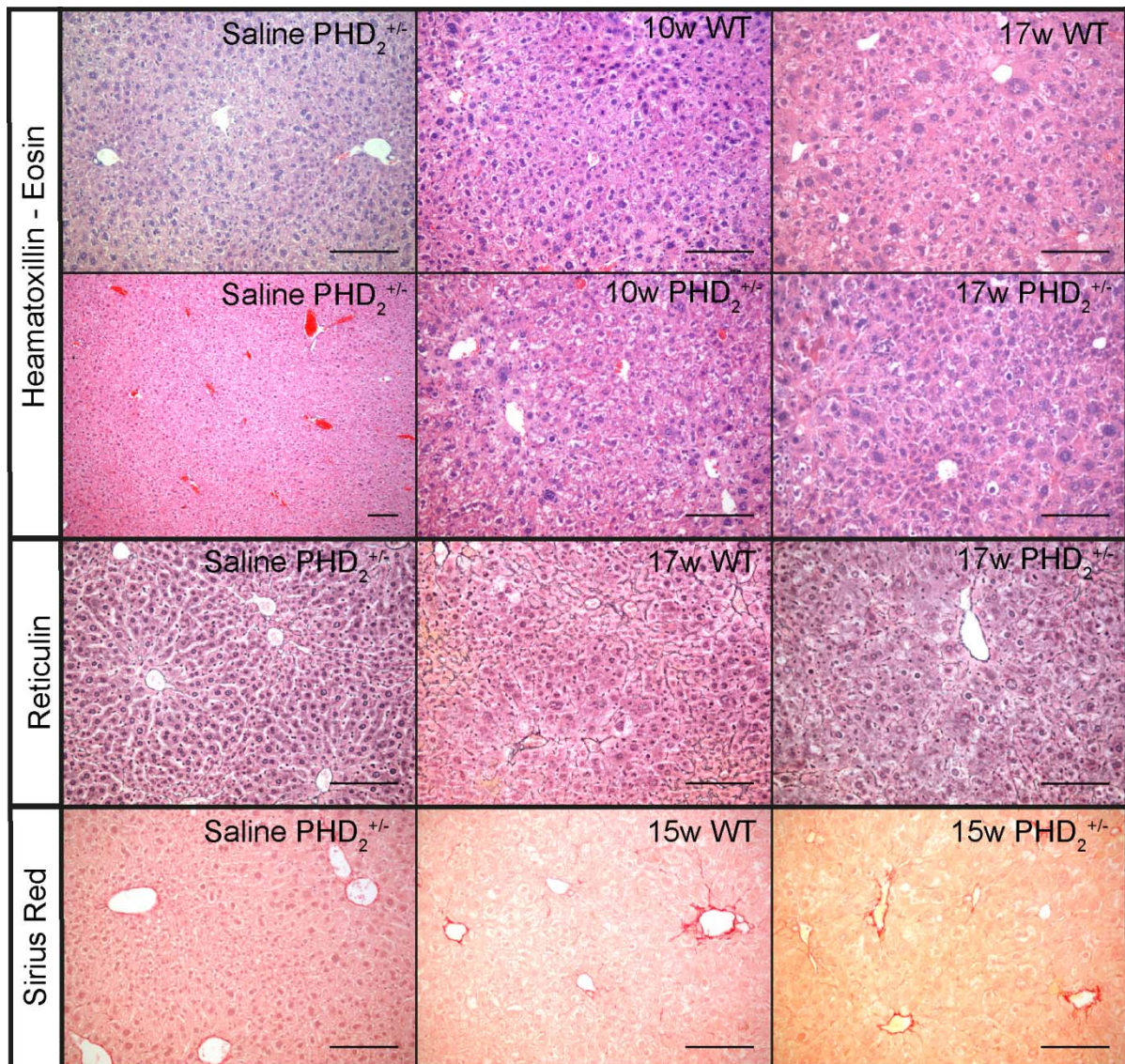


**Supplementary Figure**



**Figure S1:** Representative images for Haematoxylin-Eosin, Reticulin and Sirius red stainings showing different groups at different time points. We observe neoplastic cells from 10 weeks onwards and loss of reticulin from 15 weeks onwards in PHD<sub>2</sub><sup>+/-</sup> and WT livers. Sirius red staining showed no presence of cholangiocytic lesions. Scale bars 2000 µm