

Case report:

Rare acute mesenteric artery embolism: a case report

Y. Han, Z.G.Liu, X.M.Zhou, K.C. Wu, J. Ding, D.M. Fan*

State Key Laboratory of Cancer biology, Institute of Gastroenterology, Xijing Hospital, Fourth Military Medical University, 15 West Changle Road, Xi'an, 710032 China; Tel.: +86 29 8337 5221, Fax: +86 29 8253 9041, Email: fandaim@fmmu.edu.cn (*corresponding author)

ABSTRACT

Mesenteric artery embolism is a rare and urgent acute abdominal emergency, which is difficult to be diagnosed early and claims a very high mortality rate. Two rare cases of acute mesenteric artery embolism are reported. A 43-year-old man with history of rheumatic heart disease suffered from vomiting and diarrhea, no severe abdominal pain. Adjuvant therapy failed to relieve the symptoms. Angiography revealed superior mesenteric artery emboli. Another 66-year-old man suffered from severe abdominal pain and diarrhea. 3D CT angiography indicated embolism of inferior mesenteric artery. These cases suggest that angiography should be considered early in suspected patients with acute mesenteric artery embolism.

Keywords: Mesenteric artery, embolism, diagnosis, angiography

CASE REPORT

One male patient of 43-year-old was admitted to the hospital with the onset symptom of nausea, vomiting, and diarrhea for 4 hours. About 4 hours ago, he began to suffer from discomfort and fullness of abdomen after meal, with mild burning sensation and no obvious pain. Subsequently, nausea, vomiting and diarrhea occurred. The stool was watery at the beginning, and then mixed with blood, no blood clot or tenesmus occurred. Physical examination showed body temperature 37.9 °C, pulse rate 98 beats/min, blood pressure 150/80mmHg. Fine tremor could be touched on the left border of sternum at 3-4 ribs. Heart rate was 80-90 beats /min, heart sounded unequal and absolute anisorhythmia, and diastolic murmur could be heard on the apex

of heart. Mild swelling was seen in the belly, no gastric form and peristaltic wave, with mild tenderness on the left upper abdomen, no muscular tension and rebound tenderness, liver and spleen were out of reach, tympanitic resonance was felt, shifting dullness negative, bowel sounds active, no high-sounding gurgling sound, no edema of both lower extremities. Blood cells counts : WBC $21.2 \times 10^9/L$, N 0.836 , HGB 149g/L , PLT $137 \times 10^9/L$, Stool routine test: WBC (+), pus cells (+++), occult blood (+), X ray of the chest indicated argumentation of heart shadow, and cardiothoracic ratio was 0.58. Plain abdominal radiograph indicated many air fluid levels in the mid abdomen with inequality of size, which showed incomplete small bowel obstruction. He had an illness

history of nephritis at 7 years old and was diagnosed rheumatic heart disease a year ago, Though given symptomatic supportive therapy and gastrointestinal decompression, the symptoms were still not relieved, yet the physical sign of abdomen was obviously aggravated, and angiografin visualization of the whole alimentary tract indicated incomplete intestinal obstruction, which lied in the 4th –5th group of small bowel, enhanced computerized tomography (CT) indicated superior mesenteric artery was not visualized, which indicated vascular occlusion, thrombus, multiple hepatic cyst, cholecystitis and left

renal cyst (Figure 1a-c). Colonoscopy showed large bowel mucosa normal. Mesenteric angiography showed superior mesenteric artery occlusion (branch of jejunal artery) (Figure 1d). Local thrombolysis wasn't managed because of the complete occlusion. The symptoms were gradually relieved after administration of *Salvia miltiorrhiza* and symptomatic supportive therapy. Patient was discharged 1 month later. The diagnosis was as follows: 1, Incomplete bowel obstruction, 2, Superior mesenteric artery occlusion.3, Rheumatic heart disease and mitral valve stenosis, atrial fibrillation.

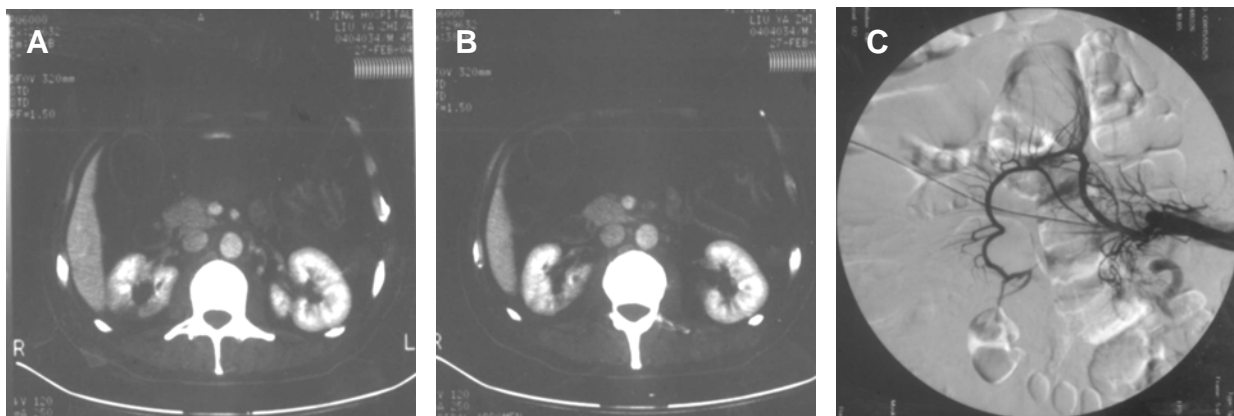


Figure 1: Computerized tomography and angiography images of superior mesenteric artery. Enhanced CT shows that superior mesenteric artery is still visible in figure 1A, but can not in figure 1B though accompanying superior mesenteric vein is still visible. Angiography reveals branch of jejunal artery from superior mesenteric artery was occluded as indicated by arrow in figure 1C.

Another male patient of 66-year-old was admitted to hospital with abdominal pain and diarrhea for 3 hours, the pain was sustained and localized, and was accompanied was dizziness, fluster, nausea and vomiting, the vomit was gastric contents, awareness of defecation occurred when defecating, and the pain relieved after defecating, the stool was watery then bloody. Physical examination: body temperature 37.8 °C ,pulse rate 90beats/min, blood pressure

140/90mmHg,heart rates 90 beats/min. Moderate tenderness was felt around left lower quadrant and peri-hylus, no muscle tension and rebound tenderness. Patient had a history of coronary artery disease for 20 years and diabetes for 2 years. Laboratory investigation: WBC $17.2 \times 10^9/L$, N 0.886 , HGB129g/L , PLT $127 \times 10^9/L$, stool routine investigation: RBC (++) , puss cell (++) , occult blood (++) . CT and 3D CT

reconstruction investigation were taken, which indicated embolism of inferior mesenteric artery, and atherosclerotic plaque was found in abdominal aorta, which indicated it was the embolus of atherosclerotic plaque that caused embolism

(Figure 2). After treatment of intravenous thrombolysis, the patient gradually got better. Colonoscopy showed the ischemic change of descending colon. The final diagnosis was: 1, Embolism of inferior mesenteric artery 2, Ischemic colitis.

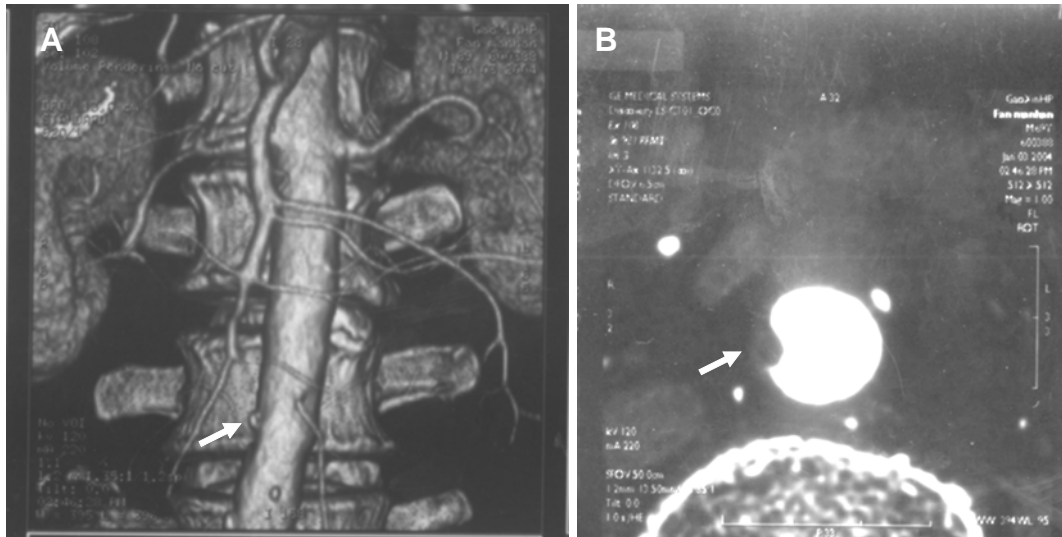


Figure 2: Computerized tomography and 3D CT angiography images of inferior mesenteric artery. Angiography shows that a branch variation of inferior mesenteric artery is occluded in figure 2A as indicated by arrow, enhanced CT scan reveals the existence of an atherosclerotic plaque of abdominal aorta in figure 1C as indicated by arrow.

DISCUSSION

Mesenteric artery embolism (MAE) is a rare and urgent acute abdominal emergency, which is difficult to be diagnosed early, and it was reported the mortality rate are approximately 70%-90%, with aggressive therapies, survival can be improved to about 55% (Brandt 2003). Just as with plain films, findings on normal CT may be normal or nonspecific in cases of ischemia or infarction. Angiography plays a critical role in both the diagnosis and management of patients with MAE (Aakhus 1966). In this paper, we report 2 rare cases with mesenteric artery embolism admitted to our department, one with atypical clinical manifestations and the other with rare embolic site, both diagnosis

were confirmed by angiography , and recovered after thrombolysis therapy.

MAE is a medical and surgical emergency that demands prompt diagnosis and a coordinated and deliberate multidisciplinary approach. Superior mesenteric artery embolism (SMAE) claims about half of the causes in acute mesenteric ischemia. However, it is rare for emboli to block inferior mesenteric artery. Superior mesenteric artery is mostly diverged from abdominal aorta at the level of first lumbar vertebra, which mainly supplies jejunum, ileum, ascending colon, transverse colon. Inferior mesenteric artery is diverged from

abdominal aorta at the third lumbar vertebra, which mainly supplies descending colon, sigmoid colon and rectum.

The embolus mainly resulted from rheumatic valvular disease, bacterial endocarditis with atrial fibrillation, and also from mural thrombosis and artery atheroma of myocardial infarction of coronary heart disease. The clinical presentations were often a typical triad: severe upper abdominal and peri-hilus pain without much finding during physical exam, non-functional cardiac disease with atrial fibrillation, evacuation of gastrointestinal tract, however, few report have shown mesenteric artery embolism without pain. The case report presented here showed a rare case of SMAE without abdominal pain, which had a history of cardiac disease and evacuation of gastrointestinal tract, and was diagnosed mesenteric artery embolism by mesenteric arteriography and CT investigation. The patient just presented the symptom of ischemic incomplete intestinal obstruction, without severe complications such as bowel necrosis, probably due to the rapid establishment of a collateral vessel. The case leads us to pay more attention to mesenteric artery embolism without typical clinical presentations. Once MAE case is suspected, angiography and CT or MRI investigation should be taken as soon as possible in order to apply thrombolysis or surgical therapy while it's not too late.

The second case reported a rare inferior mesenteric artery embolism, which was often caused by post-neoplasty of abdominal aneurysm or carcino-embolism, sometimes by inflammatory bowel disease, however, artery atheroma related inferior mesenteric artery embolism has not been reported before. After prompt angiography and CT

investigation and thrombolysis, collateral circulation was gradually established, thus avoiding the severe complications, such as bowel necrosis.

In conclusion, mesenteric artery is a curable disease with extremely demanding requirement on therapy timing, and the mortality rate could be decreased significantly if the clinicians take more aggressive steps to confirm diagnosis early (Park et al. 2002). While mesenteric arteriography has been the golden standard for the diagnosis of mesenteric occlusion, other alternatives such as contrast-enhanced computed tomography has been proposed to be a substitute (Sato et al. 2003). With the development of more useful diagnosis technology, it could be expected that the survival rate in MAE could be improved dramatically in the foreseeable future.

References

- Brandt,LJ. Mesenteric vascular disease. 2003; 2:151-65.
- Aakhus,T. The value of angiography in superior mesenteric artery embolism. Br J Radiol 1966; 39:928-32.
- Park,WM, Gloviczki,P, Cherry,KJ, Jr., Hallett,JW, Jr., Bower,TC, Panneton,JM, Schleck,C, Ilstrup,D, Harmsen,WS, Noel,AA. Contemporary management of acute mesenteric ischemia: Factors associated with survival. J Vasc Surg 2002; 35:445-52.
- Sato,O, Okamoto,H, Matsumoto,H. Emergency CT scan for the diagnosis of superior mesenteric artery embolism. Report of 2 cases. Int Angiol 2003; 22:438-40.